

Motion-compensated reconstruction for coronary imaging

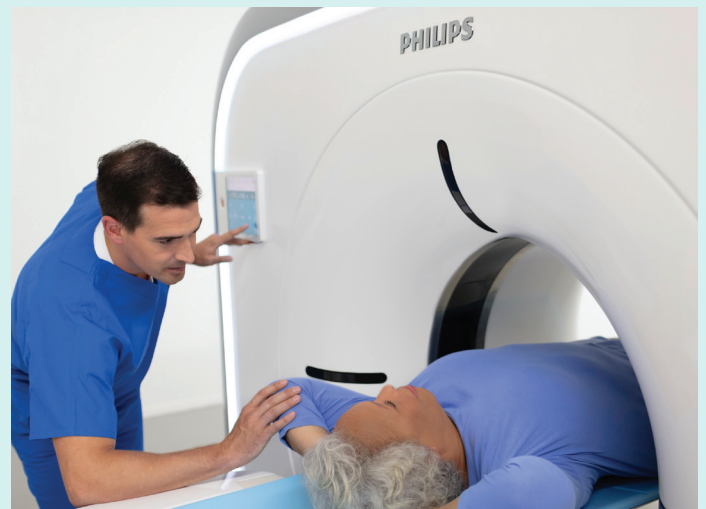Precise Cardiac

Overview

Philips Precise Cardiac is a novel approach with the ability to compensate for cardiac motion in CT imaging, improving visualization of the coronary arteries. This can help salvage some of the coronary segments deemed non-diagnostic using standard cardiac reconstructions, increasing diagnostic confidence in coronary CTA exams.

Background

Coronary computed tomography angiography (coronary CTA) has become the preferred noninvasive modality for the detection and rule-out of coronary artery disease (CAD), by providing an assessment of the coronary anatomy and visualization of atherosclerotic plaque to aid in detection of lesions that may limit blood flow to the myocardium. However, there are multiple challenges in imaging coronary arteries with the use of CT. These arteries are small with a caliber approaching 1 mm or less at their most distal ends, and they exhibit complex 3D motion during the cardiac cycle, which contributes to motion artifacts during cardiac imaging.^{1,2} In addition, the limited temporal resolution of coronary CTA is insufficient to address these motion artifacts, resulting in non-evaluable coronary segments, which impacts diagnostic performance.



Precise Cardiac compensates for cardiac motion in CT studies.

While motion artifacts are more pronounced and common at higher and variable heart rate (HR), they could also occur at lower HR as well. A common clinical practice to counter this is to administer medication to lower and stabilize the HR. Additionally, one technical approach is to increase the rotation speed of the gantry to improve the native temporal resolution of the system. However, this approach is not practical beyond a certain limit because

of the severe gravitational forces imposed upon the system. Over the years, Philips has implemented helical multicycle cardiac reconstructions to improve image quality.¹⁻³ Because it is adaptive in nature, this approach combines data from multiple cardiac cycles without any user input to optimize temporal resolution and thus improve the coronary image quality and diagnostic performance of coronary CTA.

Philips CT Smart Workflow

Precise Cardiac is one of the many AI-enabled* tools of CT Smart Workflow, which includes AI that is deeply embedded into tools clinicians use every day to be able to apply their expertise to the patient, not the process.

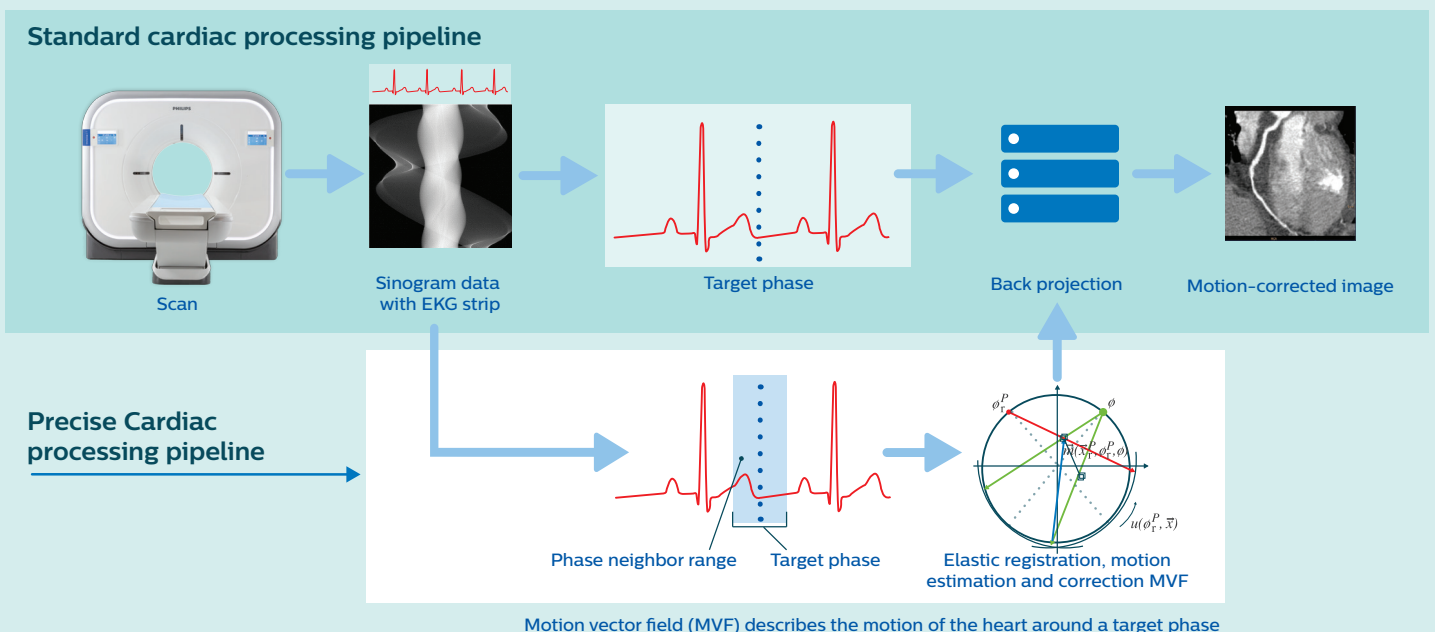
Precise Cardiac

As a technology innovation leader in cardiac imaging, Philips has recently introduced a novel reconstruction approach complementing adaptive reconstruction techniques. The motion-compensation reconstruction of Precise Cardiac offers a novel, zero-click technique generating a single series of motion-corrected images applicable to both modes of coronary CTA scans (retrospectively gated helical and prospectively gated axial [Step & Shoot Cardiac]).⁴⁻⁷

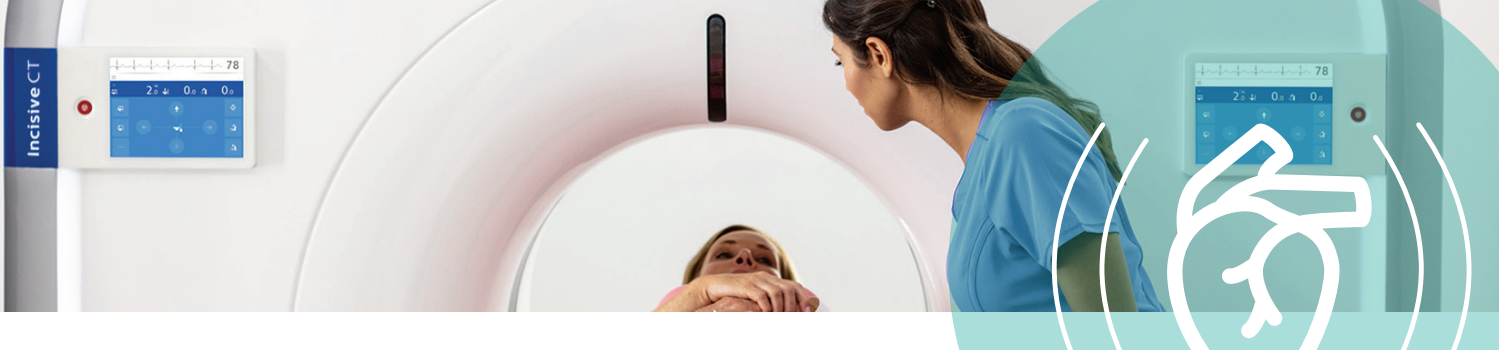This sophisticated approach avoids the need for any manual intervention by employing efficient filtering techniques in a pre-defined region around a targeted cardiac phase to identify the relevant objects and dynamically tracking their motion behavior in the localized portion of the cardiac cycle. By taking into account the displacement of structures and performing the relevant corrections as part of the back-projection process, motion-corrected images are generated.

* According to the definition of AI from the EU High-Level Expert Group.

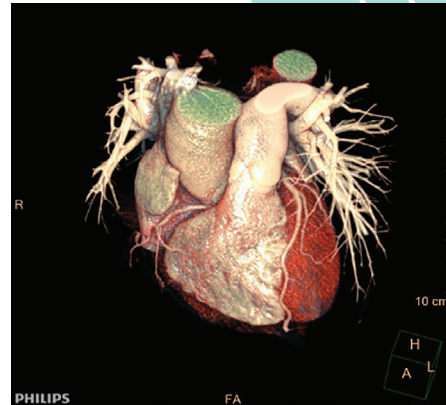
Precise Cardiac processing steps



The processing pipeline shows how Precise Cardiac corrects for cardiac motion to improve visualization in cardiac scans.



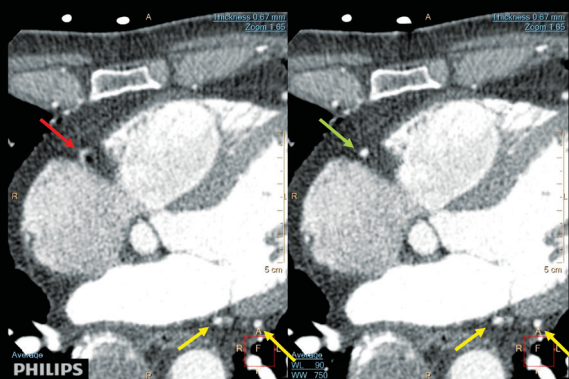
A recent pilot study of 28 patients demonstrated the effectiveness of this approach in improving the quality of visualization of all coronary arteries, while maintaining the signal-to-noise ratio (SNR) and contrast-to-noise ratio (CNR). The mean HR of the patients during the scan was 86 ± 11 bpm (range: 68–114 bpm). The resulting visualization scores were higher with the use of motion-compensation reconstruction for all coronary artery segments compared to the routine gated reconstructions.⁸



Performance

The use of Precise Cardiac demonstrates significant improvements in image quality of the entire right coronary artery (RCA), compared with standard cardiac reconstructions. Correcting for motion in the coronary arteries potentially saves a patient a repeat scan.

Philips Incisive CT



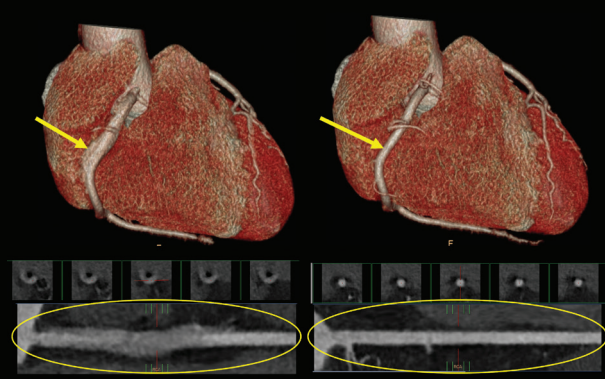
Original

Precise Cardiac

Scan parameters – 120 kVp, 697 mAs, $CTDI_{vol}$ 56.5 mGy, DLP 678 mGy* cm, effective dose 9.5 mSv ($k=0.014$)

Middle-aged patient admitted with chest pain and shortness of breath, average HR: 61 bpm.

Philips Spectral CT 7500

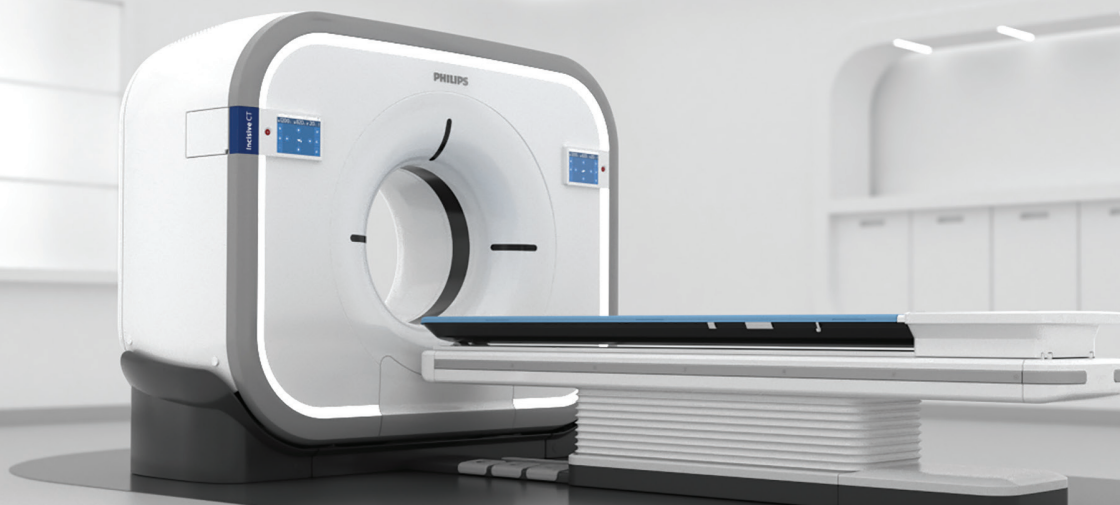


Original

Precise Cardiac

Sample images acquired in a clinical study of the Spectral CT 7500 system at Tel Aviv Sourasky Medical Center (Ichilov), Israel.

Precise Cardiac eliminated motion observed in RCA, HR: 77 bpm.



Conclusion

Philips Precise Cardiac is a novel technological innovation that features the ability to compensate for cardiac motion to improve visualization of the coronary arteries during CT imaging. Precise Cardiac can help salvage some coronary segments previously deemed nondiagnostic using standard cardiac reconstructions, thus increasing the diagnostic confidence in coronary CTA exams and potentially opening up newer applications.

References

1. Vembar M, et al. A dynamic approach to identifying desired physiological phases for cardiac imaging using multislice spiral CT. *Med Phys*. 2003;0(7):1683–93. DOI: 10.1118/1.1582812.
2. Vembar M, et al. Cardiac imaging using multislice computed tomography scanners: technical considerations. *Coron Artery Dis*. 2006;17(2):115–23. DOI: 10.1097/00019501-200603000-00004.
3. Grass M, et al. Helical cardiac cone beam reconstruction using retrospective ECG gating. *Phys Med Biol*. 2003;48(18):3069–84. DOI: 10.1088/0031-9155/48/18/308.
4. Koken P, et al. Aperture weighted cardiac reconstruction for cone-beam CT. *Phys Med Biol*. 2006;51(14):3433–48. DOI: 10.1088/0031-9155/51/14/011.
5. Grass M, et al. Fully automatic cardiac CT motion compensation using vessel enhancement. Presented at Society of Cardiovascular Computed Tomography annual meeting. 2016. Orlando, FL.
6. Grass M, et al. Fully automatic cardiac CT motion compensation using vessel enhancement. Presented at Radiological Society of North America annual meeting. 2016. Chicago, IL.
7. Van Stendaal U, et al. A motion-compensated scheme for helical cone-beam reconstruction in cardiac CT angiography. *Med Phys*. 2008;35(7):3239–51. DOI: 10.1118/1.2938733.
8. Balaney B, et al. Improved visualization of the coronary arteries using motion correction during vasodilator stress CT myocardial perfusion imaging. *Eur J Radiol*. 2019;114:1–5. DOI: 10.1016/j.ejrad.2019.02.010.

Results from case studies are not predictive of results in other cases. Results in other cases may vary.